

Diagnosis And Management Of Pulmonary Tuberculosis In Hiv With Severe Immunodeficiency

Fitri Amelia Rizki^a | Irvan Medison^b | Fenty Anggrainy^a

^aDepartment of Pulmonology and Respiratory Medicine, Faculty of Medicine, Universitas Andalas Padang, Indonesia

^bDepartment of Pulmonology and Respiratory Medicine, Dr. M. Djamil General Hospital Padang, Indonesia

*Corresponding Author: fitri.rizki.far@gmail.com

ARTICLE INFORMATION

Article history

Received (11 January 2025)

Revised (20 January 2025)

Accepted (23 January 2025)

Keywords

Pulmonary tuberculosis;

HIV;

CD4

ABSTRACT

The total number of TB cases in Indonesia is 969,000. This figure represents a 17% increase compared to 2020. SITB 2022 data shows there were 15,375 cases of co-infection of pulmonary TB with HIV. The treatment success rate for pulmonary TB co-infection with HIV in Indonesia in 2022 is 71%. This is still far from the national target of 90%.

This case report discusses a 33-years-old man with pulmonary TB and TB lymphadenitis with HIV at clinical stage 4. The CD4 count was 10 cells/mm³. The degree of immunodeficiency suffered by this patient is severe immunodeficiency. The management was to administer ATD first, followed by ART within 2 weeks after ATD was administered and well tolerated. Antituberculosis drugs was administered for 9 months due to the presence of TB lymphadenitis. Treatment evaluation showed clinical improvement and the patient did not experience IRIS. The incidence of IRIS in patients with TB is 8%-43%. Factors influencing the occurrence of IRIS include the CD4 count at the start of ART.

Introduction

The Global Tuberculosis Report 2022 noted that Indonesia is the second country with the highest number of tuberculosis (TB) cases globally. The total number of TB cases in Indonesia reached 969,000 cases (equivalent to 1 case every 33 seconds). This figure represents a 17% increase compared to 2020, which recorded 824,000 cases (Kementerian Kesehatan Republik Indonesia, 2023). Even more alarming, the death rate from TB in 2022 reached 150,000 deaths (equivalent to 1 death every 4 minutes), marking a 60% increase from 2020, which recorded 93,000 deaths. This situation highlights the urgency for swift and systematic public health interventions (WHO, 2022).

Additionally, Indonesia is also grappling with a high burden of Human Immunodeficiency Virus (HIV) cases. Between 2012 and 2016, the number of new HIV cases increased by 19,739 cases, from 21,511 cases to 41,250 cases. The total incidence of HIV in Indonesia in 2020 reached 540,000 people, most of whom were aged 15 to 49 years (Jocelyn et al., 2024). Furthermore, cases of Acquired Immunodeficiency Syndrome (AIDS) in Indonesia were reported at 114,065 cases as of December 2018 (Gumilang et al., 2022). With the dual burden of high TB and HIV prevalence, Indonesia faces a public health crisis, where these diseases exacerbate one another, leading to higher risks of morbidity and mortality. This underscores the urgency of enhancing prevention efforts, early detection, and comprehensive management of TB and HIV co-infection.

The Tuberculosis Information System (SITB) in 2022 reported at least 15,375 cases of TB coexisting with HIV infection in Indonesia. Another report from the Global Tuberculosis Report 2023 indicated 24,000 patients with TB and HIV, with an estimated 6,700 deaths among TB patients with HIV out of the total 140,700 TB deaths recorded in Indonesia (World Health Organization, 2023). At the research site, Dr. M. Djamil Hospital in Padang, the prevalence of TB-



This is an Open Access article
Distributed under the terms of the
[Creative Commons Attribution 4.0 International License](https://creativecommons.org/licenses/by/4.0/).

HIV co-infection remains significant, consistent with national trends. This reflects the ongoing challenge in addressing the dual burden of TB and HIV in both national and local healthcare settings.

HIV-TB co-infection continues to pose a major challenge in healthcare services due to its high treatment failure rate and increased risk of mortality. Research by Alayu et al. (2021) in Southern Ethiopia reported a therapy success rate of 86.4% for patients with TB-HIV co-infection. In comparison, the success rate in Indonesia was 69% in 2017, which increased slightly to 71% in 2022 (Alayu Alemu et al., 2021). However, this figure remains far from the national target of 90% for tuberculosis treatment success (Geofrey, 2020). The data emphasize the urgent need to improve both diagnosis and treatment strategies, particularly in healthcare facilities like Dr. M. Djamil Hospital, where the burden of TB-HIV co-infection is evident.

Based on the study by Blanc et al (2020) in *The New England Journal of Medicine*, there is a gap regarding the effectiveness of systematic and test-guided approaches in managing tuberculosis in HIV patients with severe immunosuppression. The study showed that while systematic treatment reduced the incidence of active TB compared to the test-guided approach, it resulted in higher rates of grade 3 or 4 adverse effects. This highlights the lack of an optimal approach that can simultaneously reduce morbidity, mortality, and treatment-related side effects in HIV patients with severe immunodeficiency. The article by Ekeng et al (2022) in the *Journal of Fungi* noted that fungal infections, such as aspergillosis and histoplasmosis, are frequently misdiagnosed as TB, particularly in high TB-burden countries. This misdiagnosis leads to delays in appropriate treatment, increased morbidity, and higher mortality rates. Furthermore, many TB cases are treated without microbiological confirmation. This underscores the need for improved diagnostic approaches to differentiate between TB and fungal infections in endemic regions. The review by Azoulay et al (2020) in *Intensive Care Medicine* highlights the challenges in diagnosing respiratory infections, including TB, in immunocompromised patients. The limited sensitivity and specificity of existing diagnostic methods, such as chest imaging or PCR tests, add to the complexity. Additionally, interactions between various infections (bacterial, fungal, viral) and immunocompromised conditions often create clinical presentations that are difficult to interpret.

Co-infection with TB and HIV poses challenges in the way the disease is diagnosed and managed in the healthcare system. Treatment challenges include drug interactions and treatment complications such as the possibility of *Immune Reconstitution Inflammatory Syndrome* (IRIS). The incidence of IRIS is reported to be 8%-43%. A contributing factor to the incidence of IRIS is the *Cluster of Differentiation-4* (CD4) value at the time of starting *anti-retroviral therapy* (ART), especially in patients with advanced stages of HIV infection, namely patients with CD4 T cell counts <200 cells/ uL which indicates severe immunodeficiency conditions.⁶ This case report discusses "Diagnosis and Management of Pulmonary Tuberculosis in HIV with Severe Immunodeficiency".

Method

This study is a case report with a descriptive-analytic approach, aiming to describe the diagnosis and management of pulmonary tuberculosis in a patient with HIV and severe immunodeficiency. The study was conducted at Dr. M. Djamil Hospital in Padang and included clinical evaluations and treatment assessments over a 9-month period from May 2023 to February 2024. This approach combines observational data from the patient's medical diagnosis and treatment outcomes, including antituberculosis drugs (ATD) and antiretroviral therapy (ART). The population of this study consists of patients diagnosed with pulmonary tuberculosis and HIV with severe immunodeficiency at Dr. M. Djamil Hospital in Padang. The sample included a 33-year-old male patient presenting with a persistent dry cough for three months, along with



an enlarging lymph node on the right side of the neck and weight loss. This patient was also diagnosed with HIV at clinical stage 4, with a CD4 count of 10 cells/mm³. The sample selection was based on inclusion criteria that involved HIV-positive patients who also had bacteriologically confirmed pulmonary TB.

The data collected were analyzed qualitatively with a descriptive approach, based on clinical improvement observed during treatment. Clinical evaluations were conducted by documenting the symptoms reported by the patient (cough, fever, night sweats, weight loss, and lymph node swelling), as well as the results of physical and radiological examinations (including chest X-rays and sputum tests). Additionally, laboratory evaluations were conducted to monitor treatment progress, focusing on CD4 count and sputum AFB (acid-fast bacilli) test results to measure the success of TB therapy. Statistical analysis was performed using descriptive data to describe patient characteristics and their clinical progression. Treatment outcomes were evaluated by comparing body weight, symptom resolution (cough, night sweats), and results from chest X-ray and AFB tests at the end of the second month and at the end of treatment.

Result

A 33-year-old male patient came to the polyclinic of Dr. M. Djamil Hospital with the results of a rapid molecular sputum test *MTB detected medium, rifampicin sensitive* and rapid HIV test with reactive results from a private hospital in Padang. The patient complained of an increasing dry cough since 3 months ago. History of coughing has been felt since 3 years ago. Other respiratory complaints, such as coughing up blood, shortness of breath, and chest pain are absent.

The patient also complained of a lump on the right neck that had been getting bigger since 1 month ago. The lump was initially the size of a peanut and is currently felt to be the size of a beaver, but not painful. Night sweats and fever have been present since 1 month ago. Weight loss is 2 kg from 57 kg to 55 kg in 1 month. There are no other complaints such as dirty tongue, liquid stools, and mouth ulcers that do not heal easily.

The patient is unmarried and works as a fisherman. He lives in Padang with his parents. Respiratory complaints in other family members were not found. The patient smoked 5 cigarettes/day for 21 years. Smoking status and Brinkmann index status are smokers with mild Brinkmann index. The patient has a history of having sexual intercourse with commercial sex workers 5 years ago. There was no history of drug use and needle sharing. There is no previous history of pulmonary TB, diabetes mellitus, and hypertension.

Physical examination showed mild pain, compos mentis consciousness, blood pressure 110/65 mmHg, heart rate 82 beats/min, respiratory rate 19 beats/min, temperature 36.7° C, SpO₂ 97%, body weight 55 kg, height 165 cm, and body mass index (BMI) 20 kg/m². Physical examination of the neck found enlarged lymph nodes at the right neck measuring 6x5 cm, skin color, movable, and no tenderness. Physical examination of the lungs static inspection obtained the right chest wall is the same as the left, dynamic movement of the right chest wall is the same as the left, palpation of the right fremitus is the same as the left, sonorous percussion in both lung fields, auscultation of bronchovesicular breath sounds, there are crackles in both lung fields and no wheezing is found.

Supporting examinations that have been carried out are *Mycobacterium tuberculosis* (MTB) rapid molecular sputum examinations with the results of *MTB detected medium, rifampicin sensitive*. Radiological examination in the form of a May 2023 thoracic photograph obtained thickening of both hillus *suggestive of pulmonary TB*. Examination of the results of fine needle aspiration biopsy of lymph nodes (FNAB) at the right neck obtained the results of granulomatous lymphadenitis which can be caused by *Mycobacterium* germs. Laboratory results and Chest X ray are attached in table 1 and figure 1.



Table 1. Laboratory results

Parameters	Results	Normal value
Hb	10.0 gr/dl	13-16 gr/dl
Leukocytes	13,960 mm ³	5,000-10,000 mm ³
Platelets	385,000/mm ³	343,000/mm ³
Diff count	0/1/2/85/4/8	0-1/1-3/2-6/50-70/20-40/2-8
Hematocrit	31%	40%-48%
GDS	129 mg/dl	50-200 mg/dl
Total protein/Albumin/Globulin	6.8/ 2.8/ 4.0 g/dl	6-8,7/3,8-5/1,3-2,7
SGOT/SGPT	72/71 u/L	<38/<41 u/L
HbSAg	Non-reactive	Non-reactive
Anti HCV	Non-reactive	Non-reactive
Anti-HIV (rapid test)	Reactive	Non-reactive
Anti HIV confirmation I	Reactive	Non-reactive
Anti HIV confirmation II	Reactive	Non-reactive
CD4	10 cells/mm ³	>500 cells/mm ³

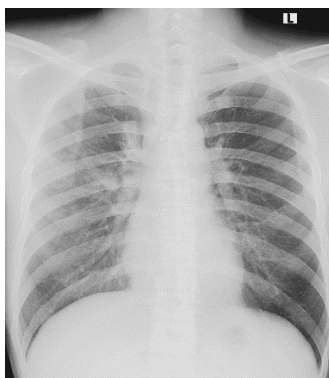


Figure 1. Thoracic photograph before ATD treatment

The patient was diagnosed with drug-sensitive bacteriologically confirmed new case pulmonary TB + TB lymphadenitis + HIV clinical stage 4. The therapy provided was antituberculosis drugs (ATD) for pulmonary TB, *antiretroviral therapy* (ART) using tenofovir disoproxil fumarate 300 mg- lamivudine 300 mg - dolutegravir 50 mg (TLD) + dolutegravir 50 mg for HIV clinical stage 4, and prophylaxis against *pneumocystis pneumoniae*. TB treatment was started on May 13, 2023 with an OAT dose of 4FDC 1x4 tablets (patient weight 55 kg) accompanied by vitamin B6 1x10 mg. *Antiretroviral therapy* (ART) TLD 1x1 tablet + dolutegravir 50 mg, and *pneumocystis pneumoniae* prophylaxis using cotrimoxazole 1x960 mg.

The patient then went to the polyclinic of Dr. M. Djamil Hospital Padang and clinical, thoracic, and bacteriological evaluations were carried out. The results of the clinical evaluation showed that the symptoms of cough and night sweats had begun to decrease, the lump on the right neck was no longer palpable. Another evaluation is that there is an increase in body weight by 10 kg from 55 kg to 65 kg.

The evaluation thoracic photograph also showed an improved picture compared to the thoracic photograph before starting treatment with Antituberculosis drugs (evaluation thoracic photograph can be seen in Figure 2). The results of acid fast bacilli (AFB) examination at the end of the 2nd month and the end of treatment were negative and negative, respectively. The patient



was then declared cured and clinical stage 4 HIV treatment was continued from the *Voluntary Counselling and Testing* (VCT) polyclinic, with TLD 1x1 tablet + dolutegravir 50 mg, and cotrimoxazole 1x960 mg.

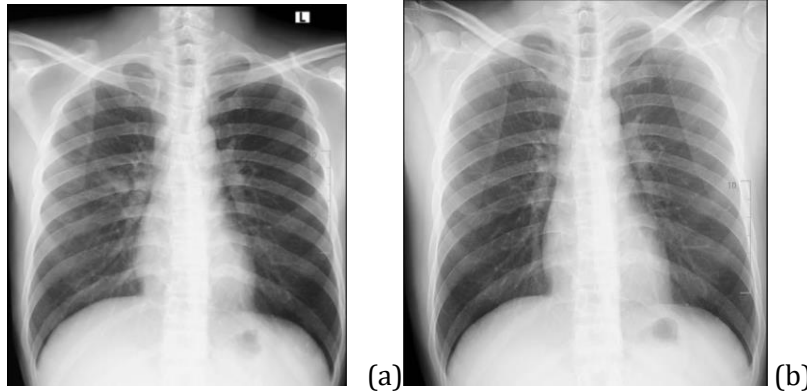


Figure 2 Evaluation thoracic photographs (a) end of 2nd month (b) end of treatment

Discussion

A 33-year-old male patient was diagnosed with a new case of bacteriologically confirmed drug-sensitive pulmonary TB + TB lymphadenitis + HIV clinical stage 4. The diagnosis of pulmonary TB was suspected based on the patient's complaints, namely complaints of dry cough since 3 months ago. The patient also complained of a weight loss of 2 kg in the last 2 months (from 57 kg to 55 kg), night sweats since 1 month ago, and a lump on the right neck that has been getting bigger since 1 month ago. There were no other complaints such as dirty tongue, liquid stools, and mouth ulcers that did not heal easily.

Physical examination of the neck found enlarged right neck lymph node measuring 6x5 cm, skin color, movable, and no tenderness. Auscultatory examination of the lungs found bronchovesicular right breath sounds, there are crackles in both lung fields and no wheezing. The patient had previously been treated at a private hospital in Padang and had a rapid molecular sputum examination with the results of *MTB detected medium, rifampicin sensitive* and rapid HIV examination with reactive results. This examination was then confirmed with 3 reagent examination and still showed reactive results.

The examination of suspicion of pulmonary TB in patients with HIV is done through rapid molecular sputum examination. The results of rapid molecular sputum examination in this case were *MTB detected medium, rifampicin sensitive*. The Indonesian Lung Doctors Association (PDPI) still recommends sputum rapid molecular sputum examination as a standard in diagnosing TB with HIV co-infection compared to sputum acid-resistant bacilli (AFB), sputum MTB culture, and tuberculin test (Perhimpunan Dokter Paru Indonesia, 2021).

A literature review conducted by Faria et al in 2019 showed an improvement in detecting pulmonary TB cases among HIV-infected individuals when using rapid molecular sputum screening. This increase in detection of pulmonary TB cases was mainly in patients with CD4 lymphocyte counts ≤ 200 cells/mm³, but other studies have suggested that CD4 lymphocyte counts ≤ 200 cells/mm³ may reduce the sensitivity of rapid molecular sputum test. The mechanism of action of rapid molecular sputum test in HIV-infected people with advanced immunosuppression has certain limitations that may be caused by the low concentration of germs in the sputum, making it potentially undetectable through rapid molecular sputum examination methods.

The sensitivity of rapid molecular sputum examination in identifying TB in HIV-positive patients ranged from 68% to 100%, with an average of 81.1%, higher than the sensitivity



provided by sputum AFB testing. Sputum AFB sensitivity ranged from 23% to 66.7%, with an average of 43.3%. The specificity of rapid molecular sputum ranged from 91.7% to 100%, with an average of 95.6%, similar to that of MTB culture as the gold standard for TB germ testing, thus concluding that rapid molecular sputum is still the standard test for TB diagnosis in HIV-positive patients (de Faria et al., 2021).

This case was found to have thickening in both lung hillus with a thoracic photo impression *suggestive of pulmonary TB*. Thoracic photography is an important test in diagnosing pulmonary TB and evaluating TB treatment. The picture found in patients with HIV can be typical or atypical, depending on the degree of immunosuppression of the patient and the number of bacilli in the lungs. Normal thoracic photographs are commonly found in HIV-positive patients. The reason may be related to decreased cellular immunity in HIV patients resulting in reduced formation of granulomas, caseous, liquefaction and cavities. Infiltrates, cavities and fibrosis are more common in HIV negative patients due to a strong inflammatory response.

Patients with CD4 T lymphocyte values <200 cells/mm³ will show a normal picture or a picture resembling primary pulmonary TB. Infiltrates will generally be localized in the lower part of the lung rather than at the apex of the lung, the opacity found is similar to consolidation in pneumonia but without cavities and fibrosis. Intrathoracic lymphadenopathy is often found in these patients, as well as diffuse infiltrates, miliary patterns, and pleural effusions. Patients with CD4 T lymphocyte counts >200 cells/mm³ will show a typical TB picture, with opacity and fibrosis predominant at the apex and cavities (Darraj, 2020).

The patient in this case was also suspected of TB lymphadenitis, so a FNAB examination of the right neck lymph node was performed. The results showed a granulomatous lymphadenitis that could be caused by *Mycobacterium* bacterial infection. Tuberculosis guidelines issued by PDPI state that TB patients who suffer from pulmonary and extrapulmonary TB simultaneously are categorized as pulmonary TB patients. The results of the HIV status examination in this patient showed reactive results, so the classification of this case is pulmonary TB with HIV positive (Perhimpunan Dokter Paru Indonesia, 2021).

TB lymphadenitis is categorized as extrapulmonary TB. A retrospective study conducted by Leeds et al. showed that the highest frequency of extrapulmonary TB in HIV patients was TB lymphadenitis (28%) and miliary TB (28%), followed by TB meningitis (22%) (Leeds et al., 2012). Another study by Kaew et al. stated that 71.8% of HIV patients suffered from severe extrapulmonary TB, namely TB meningitis and miliary TB, associated with low CD4 T lymphocyte cell values (CD4 <100 /mm³) (Kingkaew et al., 2009).

The findings of extrapulmonary TB obtained from the Sedhain et al study were 75% of cases and the findings of pulmonary TB cases were 25% of cases. The most common extrapulmonary tuberculosis was TB lymphadenitis (30%), followed by miliary TB (17%), pleural effusion (12%), miliary TB (6%), TB meningitis (4%), intestinal TB (3%), TB pericarditis (3%). This study also looked at TB findings based on CD4 T lymphocyte counts. The most common case in patients with CD4 T lymphocyte count <200 /mm³ was TB lymphadenitis (36%), followed by miliary TB (19%), pulmonary TB (15%), pleural effusion (11%). The most common case in patients with CD4 T lymphocyte count >200 /mm³ was pulmonary TB (53%), followed by TB lymphadenitis (21%), and pleural effusion (13%) (Sedhain et al., 2012).

The initial diagnosis of HIV in this case arose from the suspicion of chronic infection in the patient and manifested as a symptom of opportunistic infection, such as weight loss, enlarged lymph nodes, and coughing for more than 1 month. Guidelines issued by the Ministry of Health of the Republic of Indonesia in 2012 show the clinical symptoms of suspected HIV infection. Clinical symptoms of HIV infection can be seen in Table 2: (Kementrian Kesehatan Republik Indonesia, 2012)

Clinical symptoms of HIV infection



Clinical Symptoms of HIV Infection

General circumstances	<ul style="list-style-type: none">▪ Significant weight loss, i.e. >10% of previous total body weight▪ Fever and diarrhea that lasts >1 month▪ Extensive lymph node enlargement
Skin	The appearance of a papule-shaped, itchy skin rash, as well as a dry skin condition
Fungal infection	Fungal infections in the mouth (oral candidiasis), seborrheic dermatitis, frequently recurring vaginal candidiasis
Viral infection	Shingles, genital herpes, molluscum contagiosum, or condyloma
Respiratory distress	Chronic cough >1 month, shortness of breath, tuberculosis, recurrent pneumonia, chronic or recurrent sinusitis
Neurological disorders	Chronic unexplained headache, febrile seizures, or decreased cognitive function

In this case, the patient was in the late phase of HIV infection, which is clinical phase 3 of chronic infection. The course of HIV infection is characterized through 3 clinical phases. The early stage of HIV infection is known as acute infection, usually starting 2-6 weeks after exposure to the HIV virus. The symptoms experienced are flu-like symptoms and can last for several weeks. Other symptoms that can be experienced at this stage are fever, skin rash, sore throat, enlarged lymph node, diarrhea, joint pain, or cough.

The second stage of HIV infection is latent infection, which is an asymptomatic period. This phase generally lasts for 5-10 years and at this stage the CD4 T lymphocyte count will slowly decline, but symptoms of the disease will not yet be seen. The third stage is the chronic infection stage which is characterized by a further decline of the CD4 T lymphocyte count to below 200 cells/mm³. This stage will affect the immune system and the decrease in T lymphocytes causes the patient to fall into the AIDS condition. Patients will then complain of weight loss, prolonged fever, weakness, enlarged lymph node, chronic diarrhea, TB, fungal infections, herpes.¹⁶

Patients then undergo HIV testing which can be done with two approaches, namely HIV counselling and testing initiated by the patient themselves voluntarily or through the initiative of health workers. The rationale for HIV testing in patients with pulmonary tuberculosis is the recommendation of standard 14 of *the International Standards for Tuberculosis Care (ISTC)*. The standard states that HIV counselling and testing is recommended for all patients with TB or suspected TB, unless the patient has had a negative HIV test within the last two months (Perhimpunan Dokter Paru Indonesia, 2021).

The HIV diagnosis test in this case used 3 types of diagnostic reagents. All three tests gave reactive results, so the patient was diagnosed as HIV positive. The patient was then referred to start antiretroviral therapy. Laboratory tests used in HIV diagnosis include: (Peraturan Menteri Kesehatan Republik Indonesia Nomor 87 Tahun 2014 Tentang Pedoman Pengobatan Antiretroviral, 2014)

1. Serologic examination, consisting of :
 - a. Rapid test, using reagents that have been validated by institutions designated by the Ministry of Health. This test is able to detect antibodies to HIV-1 and HIV-2. This test only requires a smaller sample and the waiting time for results is less than 20 minutes.
 - b. *The Enzym Immunoassay (EIA)* test, identifies HIV-1 and HIV-2 antibodies by detecting the color change in the antigen-antibody reaction.



- c. The *Western Blot* test, an antibody confirmation test, is used for difficult cases or when the results of previous tests are inconclusive.
2. *Polymerase Chain Reaction* (PCR) virology test
HIV diagnostic testing in children under 18 months of age, consisting of:
 - a. *Human Immunodeficiency Virus Deoxyribonucleic Acid* (HIV DNA) qualitative *Early Infant Diagnosis* (EID), detects viral DNA directly without relying on the presence of HIV antibodies. This test is used for HIV diagnosis in infants.
 - b. Qualitative *Human Immunodeficiency Virus Ribonucleic Acid* (HIV RNA), is a test for the amount of virus in the blood. This test can be used to monitor the effectiveness of ARV therapy in adults and HIV diagnosis in infants if HIV DNA testing is not available.
3. HIV p24 antigen test, a test that identifies the p24 protein. The p24 component can usually be detected within 10-14 days of infection. This test is recommended by the *World Health Organization* (WHO) and the *Centers for Disease Control and Prevention* (CDC) as it minimizes the time needed to diagnose HIV.

This case patient is categorized in severe immunodeficiency with a CD4 count of 10 cells/mm³. CD4 count measurement is an indicator that can be used to evaluate a patient's immunodeficiency level. A decrease in CD4 count often occurs before the appearance of clinical symptoms, so it can be an early sign of disease development and progression. The classification of CD4 values is divided into 4, namely no immunodeficiency, mild immunodeficiency, moderate immunodeficiency, and severe immunodeficiency. Patients with no immunodeficiency have CD4 counts >500 cells/mm³. Patients with mild, moderate, and severe immunodeficiency have CD4 counts of 350-499 cells/mm³, 200-349 cells/mm³, and <200 cells/mm³, respectively (Peraturan Menteri Kesehatan Republik Indonesia Nomor 87 Tahun 2014 Tentang Pedoman Pengobatan Antiretroviral, 2014).

The patient was managed with ATD for pulmonary TB, ART with TLD for HIV clinical stage 4, and prophylactic therapy against *pneumocystis pneumoniae*. TB treatment was given first compared to ART. *Antiretroviral therapy* is given as soon as TB therapy is well tolerated. The rationale for giving OAT first compared to ART is to reduce the morbidity and mortality rates caused by TB in patients with HIV. PDPI guidelines state that HIV TB mortality generally occurs within the first 2 months of ATD administration. The administration of ATD before ART is in accordance with ISTC number 15, which states that in cases of TB-HIV co-infection with severe immunosuppression, ART should be initiated within 2 weeks after the start of TB treatment and no later than 8 weeks after the start of TB treatment regardless of CD4 count. Patients with HIV-TB co-infection should also receive cotrimoxazole prophylaxis to prevent other infections. Cotrimoxazole is given throughout TB treatment (Kementerian Kesehatan Republik Indonesia, 2020).

Pulmonary tuberculosis is a common form of opportunistic infection found in AIDS patients and a leading cause of death in developing countries, accounting for approximately 25% of deaths. Research on the timing of ART initiation during TB treatment was conducted in 2011 and the *Starting Antiretroviral therapy at three Points in Tuberculosis* (SAPiT) study. The study showed that ART initiation during TB treatment reduced mortality by 56% compared to ART initiation after TB treatment. More specifically, the study explained that initiation of ART within 2-4 weeks of OAT administration reduced mortality in patients with severe immunodeficiency (CD4 <50 cells/mm³). Patients with higher CD4 counts (CD4 >50 cells/mm³) showed no difference in the value of initiating ART earlier or after TB treatment (Naidoo et al., 2013).

The principle of TB treatment with HIV/AIDS is the same as without HIV/AIDS, i.e., four types of drug combinations are used in the intensive phase and two drug combinations in the continuation phase. Antituberculosis drugs are given in adequate amounts and doses. Drug interactions need to be considered because ATD generally interacts with non-nucleotide ART and



protease inhibitors. Rifampicin and nelfinavir are also not recommended to be given simultaneously because rifampicin can reduce nelfinavir levels by 82%, besides rifampicin can also reduce nevirapine levels by 37%. The patient in this case was given 1x4 tablets of ATD according to his pre-treatment body weight, which was 55 kg and adjusted every month according to the patient's weight condition.

The duration of treatment for pulmonary TB concurrent with TB lymphadenitis is 6 months and can be extended to 12 months. The treatment in this case lasted for 9 months, and the patient's clinical response included improvement in respiratory symptoms, weight gain, and complaints of a lump on the right side that was no longer palpable. Evaluation of treatment success was carried out in the same way, both in TB patients with and without HIV. The evaluation was conducted using bacteriological examination of sputum AFB performed at the end of month 2 and the end of treatment. The AFB results were negative and negative respectively. Patients were also evaluated for thoracic photographs in the same month with an impression of improvement in the thoracic photograph (Perhimpunan Dokter Paru Indonesia, 2021).

Lymph nodes are the site of both survival and reactivation of TB germs. Experimental studies in *cynomolgus* macaques conducted by Ganchua et al showed that the reduction of TB germs in lymph node was lower than the reduction of TB germs in lung granulomas using antituberculosis drugs, which was 55-fold compared to 181-fold (Ganchua et al., 2018). Another study examined the concentrations of rifampicin and isoniazid in blood, lung, granuloma and lymph node. The results showed that the anti-tuberculosis drugs had the highest concentration in the blood (rifampicin 6.95 µg/ml; isoniazid 4.11 µg/ml) and the lowest in the lymph node (rifampicin 0.03 µg/ml; isoniazid 0.21 µg/ml). This finding suggests that drug penetration is lower in the lymph node, so longer administration is expected to optimize therapy (Ganchua et al., 2020).

Evaluation of this case also showed that the patient did not have IRIS. *Immune reconstitution inflammatory syndrome* (IRIS) is a collection of clinical symptoms characterized by severe inflammation after rapid immune reconstitution following ART initiation (Quinn et al., 2020). The diagnosis of IRIS is made when a patient has been diagnosed with TB and received well-tolerated TB therapy, but clinical deterioration occurs at ART initiation.

A literature review conducted by Surendra and Manish in 2011 showed the incidence of IRIS ranged from 8%-43%. A contributing factor to the incidence of IRIS is the CD4 count at ART initiation. Low CD4 counts at ART initiation, especially in patients with clinical stage 4 HIV, increase the risk of IRIS. If IRIS occurs, short-term steroid addition of methylprednisolone 0.5-1 mg/kgBB/day is recommended and the patient should not be discontinued from ART.

Clinical manifestations of IRIS-TB generally appear within the first 3 months after starting ART and are characterized by clinical deterioration. These include enlarged lymph nodes, cold abscesses, worsening of thoracic radiology images, worsening of serositis, or worsening of respiratory symptoms, constitutional symptoms, or worsening of abdominal pain symptoms. TB-IRIS cases must also be distinguished from ART-associated TB and IRIS-TB *unmasking* cases. ART-associated TB cases are all TB cases diagnosed while the patient is on ART, provided that the patient was not receiving TB treatment prior to ART initiation and TB is diagnosed after ART administration. IRIS-TB *unmasking* cases are those patients who did not receive TB treatment at ART initiation and developed TB 3 months after ART, with worsening clinical manifestations associated with an inflammatory response, such as TB lymphadenitis or a TB abscess with prominent inflammatory features (Mahadita & Somia, 2020).

The management of HIV clinical stage 4 in this patient was ART using TLD 1x1 tablet + dolutegravir 50 mg. The standard treatment protocol for HIV is to use 2 ART combinations of *nucleotide reverse transcriptase inhibitors* (NRTIs) and a third class of drugs. This third drug class can include *non-nucleotide reverse transcriptase inhibitors* (NNRTIs) such as nevirapine and



efavirenz (EFV), protease inhibitors such as lopinavir/ritonavir (LPV/r) or tazanavir, and *integrase strand transfer inhibitors* (INSTIs) such as dolutegravir (DTG) and raltegravir (RAL) (World Health Organization, 2016).

Previous WHO recommendations suggested tenofovir, lamivudine and efavirenz (TLE) as first-line therapy for patients with newly recognized HIV. This recommendation changed in 2018, replacing efavirenz as first-line HIV treatment with dolutegravir. This was because dolutegravir showed better evidence of efficacy, higher safety, and lower risk of resistance than efavirenz (World Health Organization, 2018).

HIV and TB drug interactions should also be a concern. These interactions can reduce drug effectiveness, potentially increasing *viral load* (VL) and triggering drug resistance (due to viral replication under conditions of suboptimal drug concentration). In this case, there is a drug interaction between rifampicin and dolutegravir. Rifampicin can reduce the concentration of dolutegravir, so the recommendation given by WHO is to increase the frequency and dose of dolutegravir administration. Patients who have received KDT TLD are recommended to add dolutegravir 50 mg and consumed after 12 hours of administration of the previous KDT. (Republic of South Africa National Department Health, 2023)

The mechanism of drug interaction of rifampicin and dolutegravir is through cytochrome P450 3A4 (CYP3A4). Rifampicin is a strong inducer of the enzyme. CYP3A4 enzymes play a role in drug metabolism, including dolutegravir. Concomitant consumption of rifampicin and dolutegravir leads to an increase in the rate at which dolutegravir is broken down by the body, thereby reducing dolutegravir levels in the bloodstream. This decrease in dolutegravir levels could potentially reduce its effectiveness as ART and may increase *viral load*.

The measure of ART success is *viral load* testing at months 6, 12, and then at least annually. Treatment is considered successful if there is no detectable virus in the *viral load* test (following the standard cut off value of the testing machine). Consistent *viral load* values of more than 1000 copies/ml in consecutive months indicate failure of first-line ART and a change to second-line ART. In this case, the patient did not receive a *viral load* evaluation due to refusal and is planned for the next visit.

In this case, the patient also received 1x960 mg of cotrimoxazole. PDPI recommendations suggest that patients with HIV-TB co-infection should be given cotrimoxazole which is useful as preventive therapy against other infections during OAT administration. Cotrimoxazole therapy can also be given to patients with HIV clinical stages 3 and 4 and/or CD4 counts <200 cells/mm³. It is given until the CD4 count is >200 cells/mm³ at 2 consecutive examinations (with an interval of 6 months) or can be given for 2 years in health facilities that do not have CD4 testing. If the OAT treatment is completed and the CD4 count is >200 cells/mm³, then the administration of cotrimoxazole can be discontinued, but if the CD4 count is <200 cells/mm³, the administration is continued with the same dose. In this case, the patient completed TB treatment on February 12, 2024 and continued HIV treatment at the VCT clinic (Kementerian Kesehatan Republik Indonesia, 2023).

Conclusion

1. This case was diagnosed with drug-sensitive bacteriologically confirmed new case pulmonary TB + TB lymphadenitis + HIV clinical stage 4.
2. TB therapy in this case was FDC for 9 months due to the presence of TB lymphadenitis.
3. HIV therapy in this case is the administration of FDC TLD which is given within 2 weeks after FDC ATD.
4. Evaluation of pulmonary TB treatment in HIV clinical stage 4 of this case is through the improvement of clinical symptoms in the form of cough and night sweats that are reduced, a lump in the right neck that is no longer palpable, and an increase in body weight by 10



- kg, thoracic photo examination obtained the impression of improvement, and negative end-of-treatment sputum AFB results.
5. No IRIS was found in this case.
 6. The outcome of pulmonary TB treatment in this case was cure.

References

- Alayu Alemu, M., Yesuf, A., Girma, F., Adugna, F., Melak, K., Biru, M., Seyoum, M., & Abiye, T. (2021). Impact of HIV-AIDS on tuberculosis treatment outcome in Southern Ethiopia – A retrospective cohort study. *Journal of Clinical Tuberculosis and Other Mycobacterial Diseases*, 25. <https://doi.org/10.1016/j.jctube.2021.100279>
- Azoulay, E., Russell, L., Van de Louw, A., Metaxa, V., Bauer, P., Pova, P., Montero, J. G., Loeches, I. M., Mehta, S., Puxty, K., Schellongowski, P., Rello, J., Mokart, D., Lemiale, V., & Mirouse, A. (2020). Diagnosis of severe respiratory infections in immunocompromised patients. In *Intensive Care Medicine* (Vol. 46, Issue 2). <https://doi.org/10.1007/s00134-019-05906-5>
- Blanc, F.-X., Badje, A. D., Bonnet, M., Gabillard, D., Messou, E., Muzoora, C., Samreth, S., Nguyen, B. D., Borand, L., Domergue, A., Rapoud, D., Natukunda, N., Thai, S., Juchet, S., Eholié, S. P., Lawn, S. D., Domoua, S. K., Anglaret, X., & Laureillard, D. (2020). Systematic or Test-Guided Treatment for Tuberculosis in HIV-Infected Adults. *New England Journal of Medicine*, 382(25). <https://doi.org/10.1056/nejmoa1910708>
- Darraj, M. (2020). Pulmonary Tuberculosis among HIV/AIDS Patients: Chest X-ray Characteristics. *Suez Canal University Medical Journal*, 23(1). <https://doi.org/10.21608/scumj.2020.36013.1014>
- de Faria, M. G. B. F., de Paula Andrade, R. L., Camillo, A. J. G., de Souza Leite, K. F., Saita, N. M., Bollela, V. R., de Rezende, C. E. M., & Monroe, A. A. (2021). Effectiveness of GeneXpert® in the diagnosis of tuberculosis in people living with HIV/AIDS. *Revista de Saude Publica*, 55. <https://doi.org/10.11606/S1518-8787.2021055003125>
- Ekeng, B. E., Davies, A. A., Osaigbovo, I. I., Warris, A., Oladele, R. O., & Denning, D. W. (2022). Pulmonary and Extrapulmonary Manifestations of Fungal Infections Misdiagnosed as Tuberculosis: The Need for Prompt Diagnosis and Management. In *Journal of Fungi* (Vol. 8, Issue 5). <https://doi.org/10.3390/jof8050460>
- Ganchua, S. K. C., Cadena, A. M., Maiello, P., Gideon, H. P., Myers, A. J., Junecko, B. F., Klein, E. C., Lin, P. L., Mattila, J. T., & Flynn, J. A. L. (2018). Lymph nodes are sites of prolonged bacterial persistence during Mycobacterium tuberculosis infection in macaques. *PLoS Pathogens*, 14(11). <https://doi.org/10.1371/journal.ppat.1007337>
- Ganchua, S. K. C., White, A. G., Klein, E. C., & Flynn, J. A. L. (2020). Lymph nodes—The neglected battlefield in tuberculosis. In *PLoS Pathogens* (Vol. 16, Issue 8). <https://doi.org/10.1371/JOURNAL.PPAT.1008632>
- Geofrey, S. (2020). *Factors Influencing Tuberculosis Treatment Outcomes in HIV Positive and HIV Negative Patients in Surabaya Indonesia*. Universitas Airlangga.
- Gumilang, R. R., Indriati, D. W., Diyantoro, D., & Sundari, A. S. (2022). The Occurance of Tuberculosis Infection among Newly HIV Diagnosed Patient in Indonesia. *Open Access Maced J Med Sci*, 10(A), 893–896.
- Jocelyn, Nasution, F. M., Nasution, N. A., Asshiddiqi, M. H., Kimura, N. H., Siburian, M. H. T., Rusdi, Z. Y. N., Munthe, A. R., Chairenza, I., Ginting Munthe, M. C. F. B., Sianipar, P., Gultom, S. P., Simamora, D., Uswanas, I. R., Salim, E., Khairunnisa, K., & Syahputra, R. A. (2024). HIV/AIDS in Indonesia: current treatment landscape, future therapeutic horizons, and herbal approaches. In *Frontiers in Public Health* (Vol. 12). <https://doi.org/10.3389/fpubh.2024.1298297>



- Kementerian Kesehatan Republik Indonesia. (2020). *Pedoman Nasional Pelayanan Kedokteran Tatalaksana Tuberkulosis*. Kementerian Kesehatan RI.
- Kementerian Kesehatan Republik Indonesia. (2023). *Petunjuk Teknis Kolaborasi TBC HIV*. Kementerian Kesehatan RI.
- Kemertrian Kesehatan Republik Indonesia. (2012). *Pedoman Nasional Tatalaksana Klinis Infeksi HIV dan Terapi Antiretroviral*. Kementerian Kesehatan RI.
- Peraturan Menteri Kesehatan Republik Indonesia Nomor 87 Tahun 2014 Tentang Pedoman Pengobatan Antiretroviral, (2014).
- Kingkaew, N., Sangtong, B., Amnuaiophon, W., Jongpaibulpatana, J., Mankatittham, W., Akksilp, S., Sirinak, C., Nateniyom, S., Burapat, C., Kittikraisak, W., Monkongdee, P., & Varma, J. K. (2009). HIV-associated extrapulmonary tuberculosis in Thailand: epidemiology and risk factors for death. *International Journal of Infectious Diseases*, 13(6). <https://doi.org/10.1016/j.ijid.2008.11.013>
- Leeds, I. L., Magee, M. J., Kurbatova, E. V., Del Rio, C., Blumberg, H. M., Leonard, M. K., & Kraft, C. S. (2012). Site of extrapulmonary tuberculosis is associated with HIV infection. *Clinical Infectious Diseases*, 55(1). <https://doi.org/10.1093/cid/cis303>
- Mahadita, G. W., & Somia, I. K. A. (2020). Patogenesis dan diagnosis immune reconstitution inflammatory syndrome tuberculosis. *Intisari Sains Medis*, 11(3), 1492–1499.
- Naidoo, K., Baxter, C., & Abdool Karim, S. S. (2013). When to start antiretroviral therapy during tuberculosis treatment? In *Current Opinion in Infectious Diseases* (Vol. 26, Issue 1). <https://doi.org/10.1097/QCO.0b013e32835ba8f9>
- Perhimpunan Dokter Paru Indonesia. (2021). *Tuberkulosis Pedoman Diagnosis dan Penatalaksanaan di Indonesia*. Perhimpunan Dokter Paru Indonesia.
- Quinn, C. M., Poplin, V., Kasibante, J., Yuquimpo, K., Gakuru, J., Cresswell, F. V., & Bahr, N. C. (2020). Tuberculosis iris: Pathogenesis, presentation, and management across the spectrum of disease. In *Life* (Vol. 10, Issue 11). <https://doi.org/10.3390/life10110262>
- Republic of South Africa National Department Health. (2023). *ART Clinical Guidelines for the Management of HIV in Adults, Pregnancy, and Breastfeeding, Adolescent, Children, Infants, and Neonates*. Republic of South Africa National Department Health.
- Sedhain, A., Ramapuram, J., Adhikari, P., & Rao, S. (2012). Clinical Presentation of Tuberculosis in HIV Positive Patients in Relation to CD4 Counts. *IDWeek 2012 Meeting of the Infectious Diseases Society of America*, 30(8).
- WHO. (2022). *Global Tuberculosis Report 2022*. World Health Organization. <https://www.who.int/news-room/fact-sheets/detail/tuberculosis>
- World Health Organization. (2016). *Consolidated Guidelines on the Use of Antiretroviral Drugs for Treating and Preventing HIV Infection: Recommendations for a Public Health Approach. 2nd edition*. World Health Organization.
- World Health Organization. (2018). *HIV Treatment: Update Recommendations on First-Line and Second-Line Antiretroviral Regimens and Post-Exposure Prophylaxis and Recommendations on Early Infant Diagnosis of HIV*. World Health Organization.
- World Health Organization. (2023). *Global Tuberculosis Report 2022*. World Health Organization.
- World Health Organizations. (2007). *WHO Case Definitions of HIV For Surveillance and Revised Clinical Staging and Immunological Classification of HIV-Related Disease in Adults and Children*. WHO. <http://www.who.int/hiv/pub/guidelines/HIVstaging150307.pdf>

